

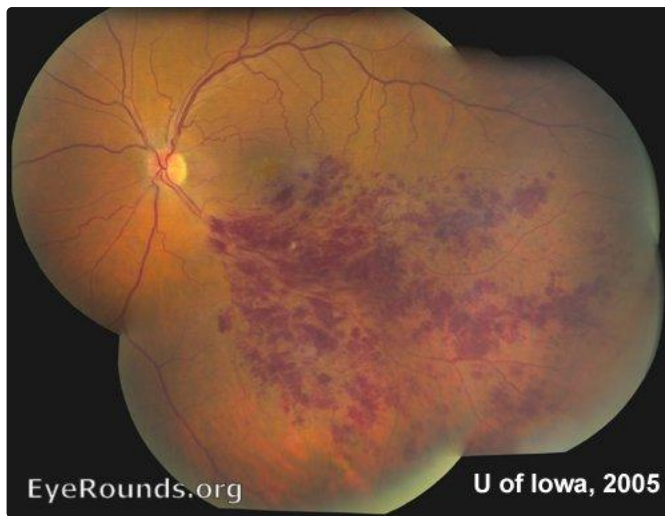
Branched Retinal Vein Occlusion (BRVO)

Category(ies): Retina

Contributor: Christopher C. Robinson, MD and [Jordan M. Graff, MD](#)

Posted: February 8, 2008

Classic sectoral hemorrhages are well-visualized in this case of Branched Retinal Vein Occlusion (BRVO). This condition is commonly associated with hypertension.



[Enlarge](#)

[Download](#)

BRVO (Branched Retinal Vein Occlusion)

Category(ies): Retina

Contributor: [Andrew Goldstein, MD](#) and [Michael D. Abramoff, MD, PhD](#)

Contributor: Sarah Skiles, CRA

Posted: April 7, 2022

This series of images was obtained in a 69-year-old man who presented for a routine eye examination and reported a remote history of branch retinal vein occlusion (BRVO). He was asymptomatic with an uncorrected distance visual acuity of 20/20 in both eyes. On his initial examination he was noted to have a large area of peripheral neovascularization elsewhere (NVE). Scatter laser photocoagulation was applied to the large area of capillary non-perfusion anterior to the NVE in order to reduce the risk of hemorrhage.



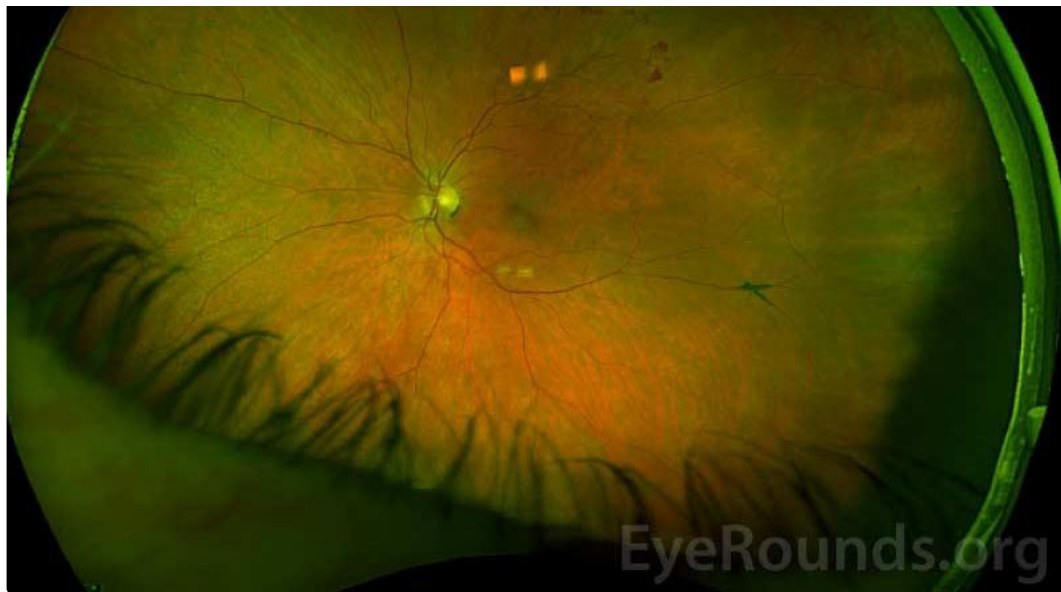

Figure 1: Optos widefield imaging of the left eye demonstrates superior temporal retinal neovascularization elsewhere (NVE) as indicated by the white arrow.

[Enlarge](#) [Download](#)

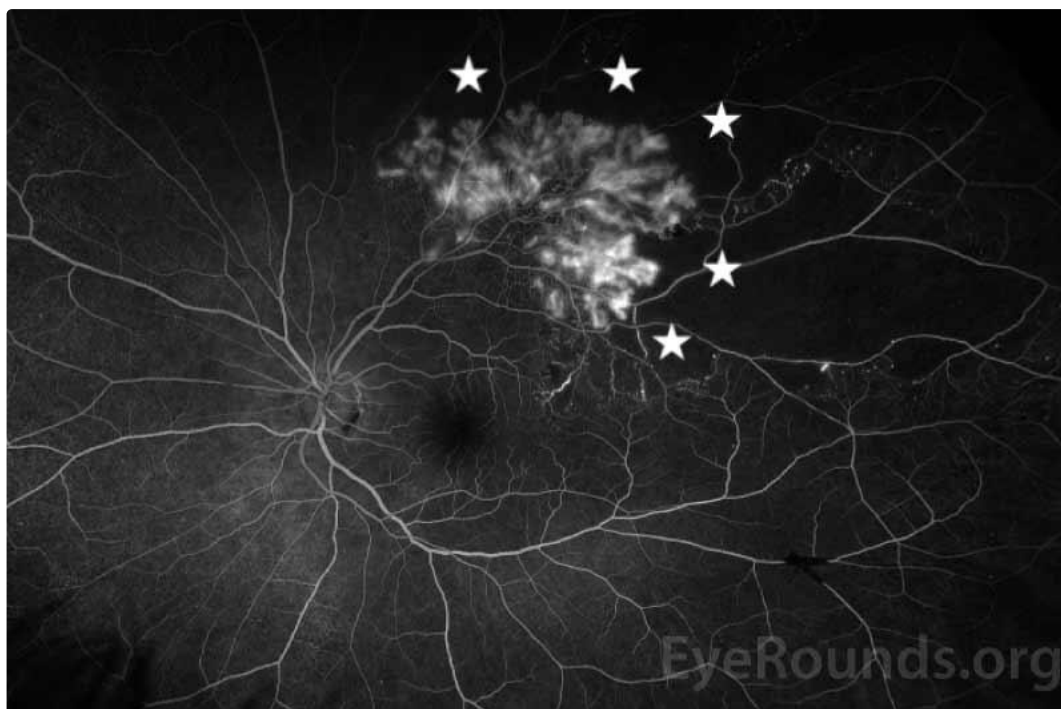


Figure 2: Optos widefield fluorescein angiography during the arteriovenous phase demonstrates neovascularization with mild leakage and capillary non-perfusion of the surrounding retina (marked by white stars).

[Enlarge](#) [Download](#)



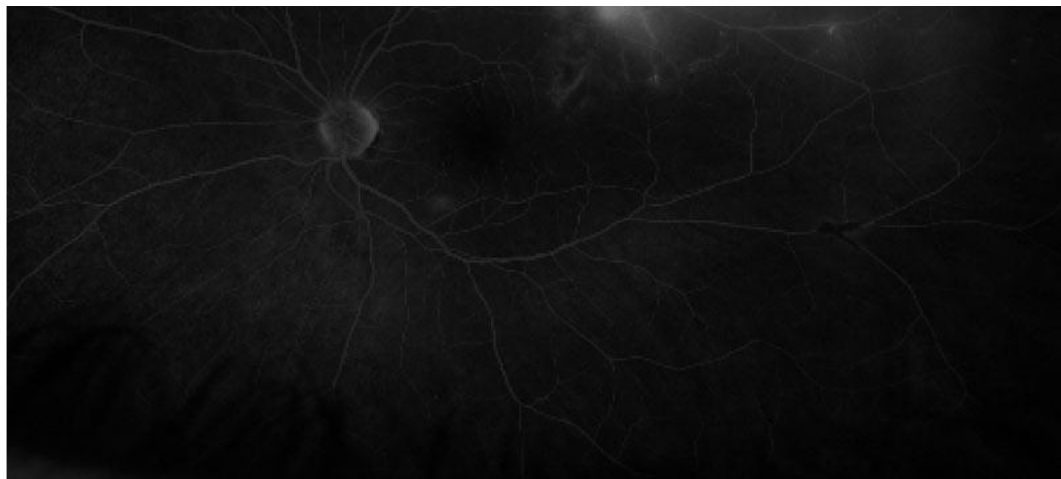

Figure 3: Optos widefield fluorescein angiography during the late phase shows continued superior temporal hyperfluorescence due to leakage from the neovascular vessels.

[Enlarge](#)

[Download](#)

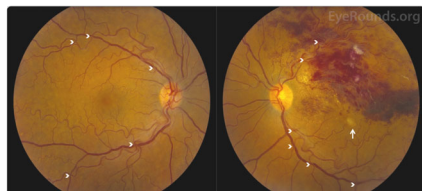
Image Permissions:



Ophthalmic Atlas Images by [EyeRounds.org](https://www.eyeforums.org), [The University of Iowa](https://www.theuniversityofiowa.edu) are licensed under a [Creative Commons Attribution-NonCommercial-NoDerivs 3.0 Unported License](https://creativecommons.org/licenses/by-nc-nd/3.0/).



Related Articles



[Related Case: Branch Retinal Vein Occlusiony](#)

Address

University of Iowa
Roy J. and Lucille A. Carver College
of Medicine
Department of Ophthalmology and
Visual Sciences
200 Hawkins Drive
Iowa City, IA 52242

[Support Us](#)

Legal

Copyright © 2019 The University of
Iowa. All Rights Reserved
[Report an issue with this page](#)
[Web Privacy Policy](#) |
[Nondiscrimination Statement](#)

Related Links

[Cataract Surgery for Greenhorns](#)
[EyeTransillumination](#)
[Gonioscopy.org](#)
[Iowa Glaucoma Curriculum](#)
[Iowa Wet Lab](#)
[Patient Information](#)
[Stone Rounds](#)
[The Best Hits Bookshelf](#)

EyeRounds Social Media

Follow



Receive notification of new cases,
[sign up here](#)
[Contact Us](#)
[Submit a Suggestion](#)

